

# Surgical Treatment Options for Lower Eyelid Aging

Joe Niamtu III, DMD

The lower eyelid and associated anatomy represent a complex structure that is key in facial aging and rejuvenation. There are numerous ways to address this region and some of the more common treatment options are discussed in this article. A review is presented of the diagnosis and popular treatment options to address the most common aspects of eyelid aging. The author has performed cosmetic lower eyelid surgery using transconjunctival blepharoplasty with skin resurfacing for the past 12 years, with pleasing results and low complications. Lower eyelid rejuvenation is one of the most commonly requested procedures in a cosmetic surgery practice. A firm understanding of the complex anatomy of this region is paramount to successful treatment. Although many methods exist for addressing this region, some techniques are more prone to postoperative complications. The author has had continued success with hundreds of patients by performing transconjunctival lower eyelid blepharoplasty with CO<sub>2</sub> laser resurfacing, chemical peels, or skin-pinch procedures. These procedures are safe, predictable, and have a place in the armamentarium of contemporary cosmetic surgeons.

**D**ermatochalasis is the crepey, wrinkled, loose, and sun damaged skin of the eyelids. Because age-associated changes to the upper face often present earlier than age-associated changes to the lower face, it is not uncommon for the cosmetic surgery practitioner to see younger patients who are unhappy with their lower eyelids. This complaint usually begins in one's late 30s and persists throughout life (Figure 1).

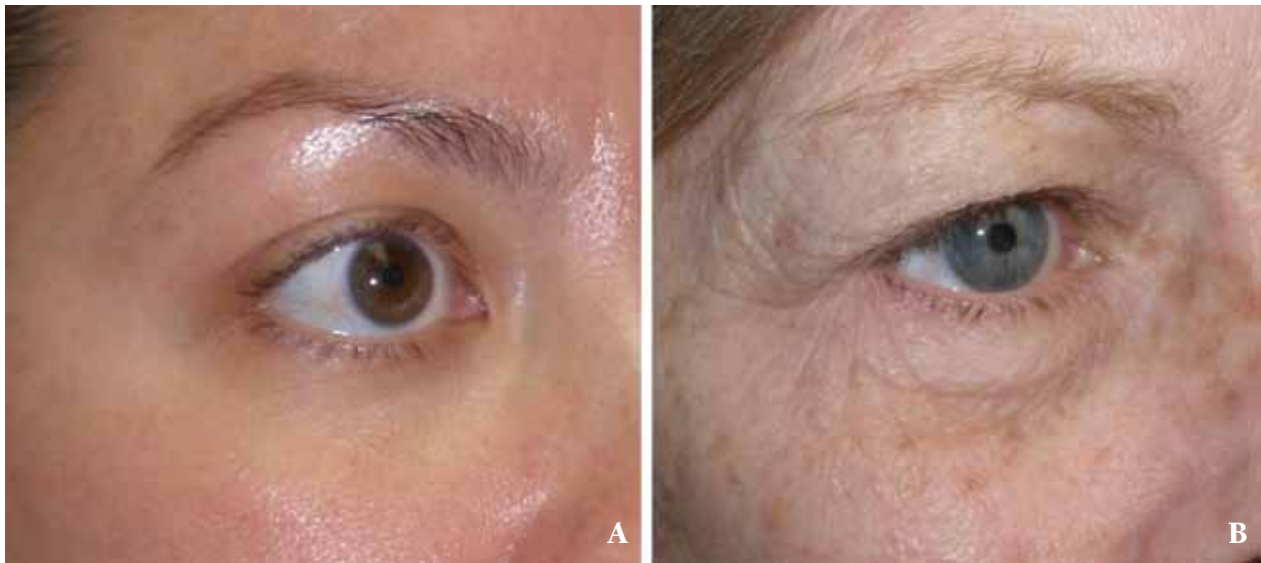
The lower eyelid system is a complex organization of bone, skin, muscle, fat, and connective tissue that undergoes many well-recognized changes during the aging process. This has to do with many factors, including the descent of the malar fat pad, atrophy of the periorbital fat over the inferior orbital rim, pseudoherniation of the periorbital fat pads, and actinic skin damage. One can generalize the majority of these changes as volume loss, volume rearrangement, and soft tissue degeneration.

---

*Dr. Niamtu is in private practice, specializing in oral/maxillofacial and cosmetic facial surgery, Richmond, Virginia.*

*The author reports no conflict of interest in relation to this article.*

The basis of this article concerns skin aging and its surgical correction, but discussion of the periorbital fat is germane to the understanding of the aging process and its correction. The periorbital fat is an essential evolutionary system that serves in part to cushion the globe within its bony orbit. The upper eyelid has 2 fat compartments and the lower eyelid complex has 3 fat compartments (Figure 2). These fat compartments (or fat pads) are referred to as the medial (or nasal), central, and lateral (or temporal). These collections of periorbital fat are posterior to the orbital septum, which is connective tissue that represents a continuation of the periosteum. As we age, the orbital septum weakens and allows the 3 periorbital fat pads to protrude anteriorly, which causes distinct bulges that are easily visible through the thin orbicularis oculi muscle and lower eyelid skin. The lower lid skin is among the thinnest of the body and can be as thin as 0.2 mm.<sup>1</sup> In addition to the fat bags that patients complain about, dark circles are also frequently mentioned by patients who are seeking rejuvenation. These dark circles frequently represent shadowing from overhead light because the protruding fat pads cause a shadow under the lower eyelids. This can be differentiated from actual skin pigmentation by showing



**Figure 1.** A 35-year-old woman with a youthful eyelid complex (A) and a 55-year-old woman with an aging eyelid complex (B).

the patient 2 pictures of their eyes; one taken with a flash and one without. This will help educate the patient on the cause of the dark circles. Actual pigmentation problems can exist that contribute to the dark circles and can range from actual epidermal and dermal pigmentation, venous congestion from sinus problems, or the underlying vasculature simply showing through the extremely thin skin of the lower lid. Some ethnic groups may have extreme deep dermal pigmentation, which is very difficult or impossible to improve. On the other hand, the average patient has a combination of shadowing from fat protrusion,

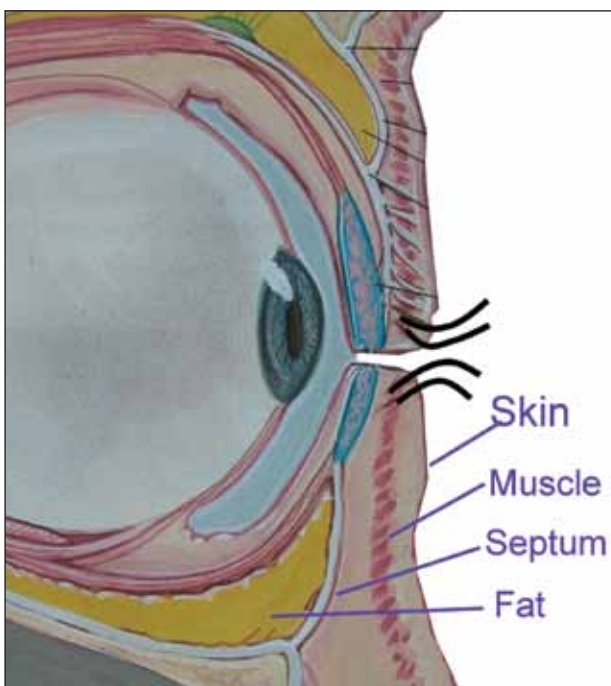
as well as actinic dyschromia, which will respond well to the procedures described in this article. In addition, extravasation of red blood cell hemosiderin can stimulate melanocytes, thus increasing pigment.

Many modalities of lower eyelid rejuvenation have been described, including surgical blepharoplasty,<sup>1</sup> chemical peels,<sup>2</sup> laser skin resurfacing,<sup>1</sup> radiofrequency tightening,<sup>3-5</sup> intense pulsed light,<sup>6</sup> filler injections,<sup>7</sup> and botulinum toxin for orbicularis hypertrophy and increasing the orbital aperture.

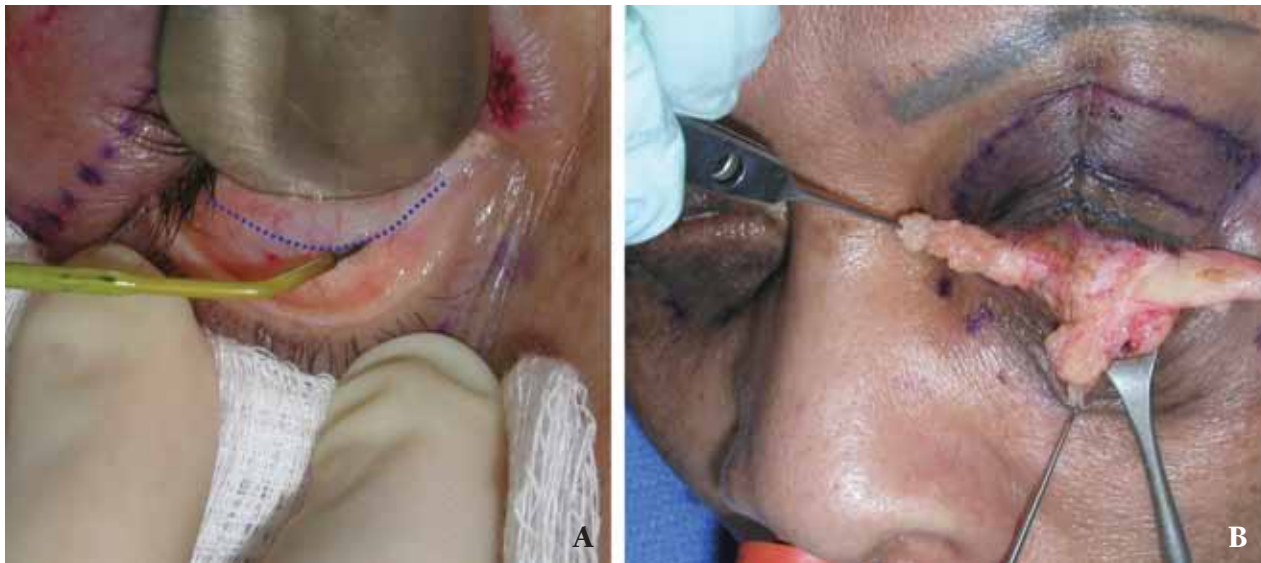## PHYSICAL EXAMS AND PRESURGICAL CONSIDERATIONS

Successful treatment of the aging eyelid requires a firm knowledge of the anatomy and pathophysiology of the periorbital. In the evaluation phase, this author examines and records the following: history of eye pathology; visual acuity exam; degree of lower eyelid laxity; quality of eyelid skin; presence or absence of orbicularis oculi hypertrophy; degree of fat protrusion; extraocular muscle function; tear production; Bell phenomenon; and corneal reflex.

Fat removal remains the most commonly utilized surgical procedure for reducing and recontouring prolapsed periorbital fat pads. Accessing the fat can be performed transcutaneously or transconjunctivally. Transcutaneous approaches, although popular, are more problematic for lower eyelid malposition. This usually results from overexcision of the skin or scarring of the middle lamella (orbital septal layer) and is manifested in a rounded canthus, sclera show, the appearance of the lower lid being pulled down, and in some cases a lagophthalmos (inability to close the eyelids). This is not only an aesthetic problem and can lead to dry eye problems.



**Figure 2.** The 2 fat compartments of the upper eye and the 3 fat compartments of the lower eyelid.



**Figure 3.** A typical transconjunctival incision using a radiowave microneedle that extends from the lacrimal punctum to the lateral canthus, approximately 4 mm below the inferior tarsus (A), with the medial central and lateral fat pads dissected intraoperatively (B).

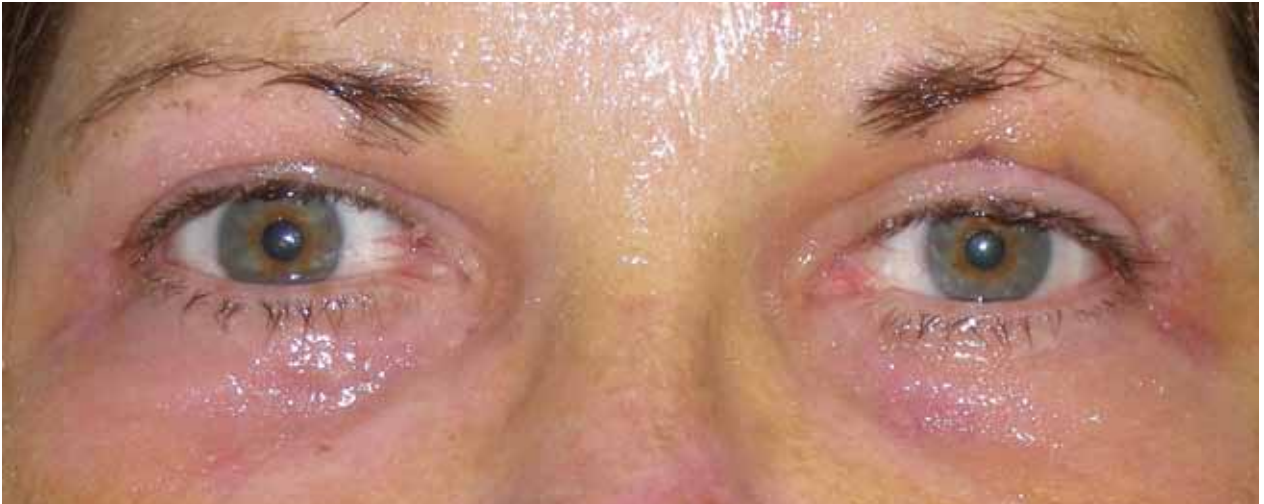The transconjunctival approach offers the advantages of a hidden incision and the ability to access the periorbital fat pads without violating the orbital septal layer. Lower eyelid malposition is not a consideration with this surgical approach. This surgical approach does have a somewhat steeper learning curve than the transcutaneous approach because the fat pads are frequently more difficult to isolate; however, with experience, this is a preferable approach. This approach is done by first injecting local anesthesia through the conjunctiva into the fat pads. The lower eyelid is then retracted and an incision is made through the conjunctiva and the capsulopalpebral fascia (lower lid retractors) from the punctum to the lateral canthus (Figure 3A). Using a CO<sub>2</sub> laser or a radiowave microneedle provides cutting with simultaneous hemostasis and reduces the procedural blood loss to several drops (Figure 3A). The surgeon then bluntly dissects posterior to the orbital septum (this is a retroseptal approach) until the individual fat pads are isolated (Figure 3B). In the average patient, once the fat capsule is located, the fat pad will herniate into the incision and be easily accessed. The medial fat pad is frequently more difficult to locate, especially for the novice surgeon. This fat pad lies medial to the inferior oblique muscle, which can serve as a landmark. The central fat pad is separated from the lateral fat pad by the arcuate expansion. Once the fat pads are located, they can be conservatively reduced or recontoured with the laser, radiowave microelectrode, or with a scalpel or scissors. Caution must be utilized to avoid aggressively stretching or tearing the fat pads because they can be quite vascular. If a vessel is inadvertently violated and the fat pad stump retracts deep into the orbit, the bleeding can be difficult

to control. Unchecked bleeding in the orbit can lead to retrobulbar hematoma and blindness and is considered an ophthalmic emergency. When the fat has been treated, the incision is passively approximated and no sutures are necessary because the lower lid compresses the wound edges, which heal rapidly.

Although fat removal is the most common modality to address pseudo-herniation, it can create a hollowed lower lid which actually makes the aging process look worse. Some surgeons prefer to simply shrink the fat back into the orbit with a laser or electrosurgery, whereas others advocate septal repair or fat repositioning.<sup>8</sup> During procedures where fat is repositioned, the fat pads are not removed but rather repositioned to fill in the tear trough region. This is done by dissecting the fat pads, making a pocket over the lower orbital rim, and then fixating the fat in place to serve as volume filler. Although this sounds like a positive treatment method, it can be very technique dependant and many surgeons say that it is not a lasting result. Other surgeons use a hybrid lower lid technique where they remove and recontour the lower lid fat, then harvest body fat and reinject it into the tear trough (nasojugal crease) region. This allows surgeons to reduce the protruding fat and fill the atrophic region along the infraorbital rim.

### TREATING EXCESS SKIN

Some patients manifest hereditary fat pad protrusion manifested by bulging lower eyelid fat at a very young age. Although these rare patients may benefit from fat reduction only, virtually every other case of lower eyelid aging will require attention to the aging skin of the lower eyelid. As stated previously, the thin skin of the lower eyelid



**Figure 4.** Patient 7 days after 2 high-fluence, high-density, nondebrided passes of the lower eyelids. Not all patients heal this quickly after aggressive CO<sub>2</sub> laser treatments, but this result is indicative of the faster rate of healing when not debriding the char between passes.

undergoes cutaneous aging manifested by wrinkling, texture changes, and dyschromia. Numerous surgical and nonsurgical techniques exist to address these issues.

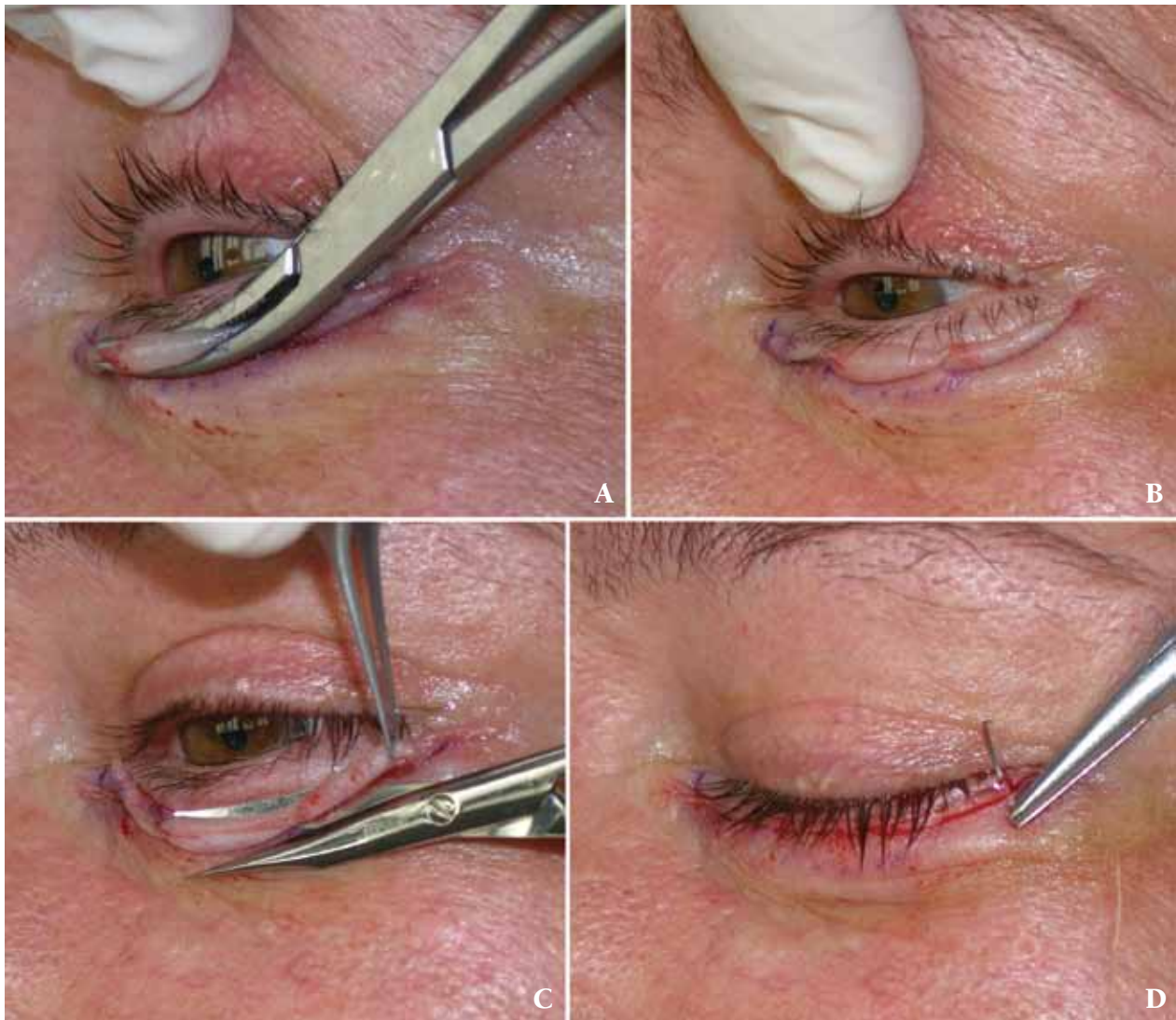As discussed, the transcutaneous subciliary approach allows direct access to the fat pads, as well as provides the ability to excise excess skin. The problems with lower eyelid malposition with this approach have been previously addressed. Overestimating excess skin and overzealous excision of skin or muscle via this approach can further contribute to lower eyelid malposition.

The author prefers the transconjunctival approach to the fat pads; however, this technique does not address the eyelid skin or hypertrophic orbicularis muscle bulging. If a hypertrophic orbicularis muscle contributes to poor lower lid aesthetics, then the transcutaneous subciliary approach may be advantageous because skin and muscle excision are an inherent part of the procedure. Again, the transconjunctival approach does not involve skin or muscle excision. The excess, aging skin must be treated by additional modalities. Three common means of rejuvenating lower eyelid skin are chemical peels, laser skin resurfacing, and skin excisions. Each of these techniques has relative advantages and disadvantages and will be discussed individually.

In the author's experience and opinion, CO<sub>2</sub> laser skin resurfacing is the absolute most effective means of rejuvenating aging eyelid skin. The CO<sub>2</sub> laser is an ablative treatment that literally vaporizes the epidermis and extends into the dermis. The advantages are the generation of new skin and collagen, the direct ablation of pigmented skin (unless extremely deep pigment), and thermal tightening of the crepey eyelid skin. Because the surgeon is essentially making new skin, the level of rejuvenation is impressive. This improvement comes

with a more formidable recovery. It is well known that laser skin ablation takes almost 2 weeks to reepithelialize, requires significant wound care, and can lead to extended erythema. The author has improved these problems by discontinuing the debriding of the laser eschar between laser passes. Although it was previously thought that leaving the char between passes would act as a heat sink and thereby produce uncontrolled thermal damage, the author has refuted this with clinical and histologic studies.<sup>9</sup> By not debriding, the charred skin serves a biologic dressing and reduces pain and wound care. In addition, the use of gauze to debride an already lasered area only serves as a further insult on the damaged tissue and prolongs erythema and recovery. By not debriding between passes, it is not uncommon for the average patient to be wearing makeup by days 7 or 8. The skin is treated with 2 passes (without debriding between passes) using a computerized pattern generator with settings of 80 j/cm<sup>2</sup> and a density of 6 (30% overlap). Postoperative care is limited to open wound care using a petrolatum product. Figure 4 shows the lower eyelids of a patient 7 days postresurfacing who was treated without debriding between passes.

Other laser technologies are also available in the treatment of aging eyelid skin, which are less aggressive than CO<sub>2</sub> resurfacing but offer other advantages. Fractionated resurfacing produces microcolumns of laser penetration while leaving intact skin bridges. This technology may be beneficial in the younger patient as a solitary skin tightening procedure or with multiple treatments in more aged skin. A newer fractionated 1550-nm erbium-doped technology has been reported by some physicians as producing significant tightening of the eyelids. This modality also requires multiple treatments but shows promise for continuing development.



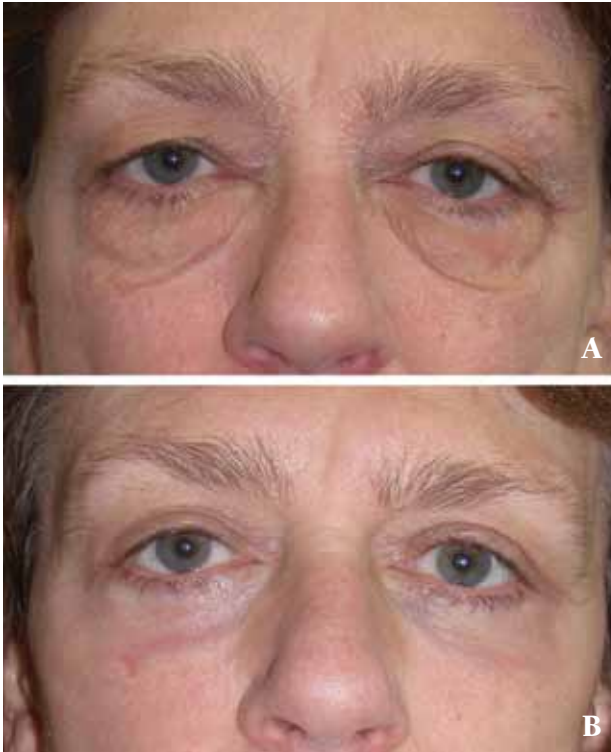**Figure 5.** A hemostat pinching the excess skin of the lower eyelid (A), with the column of excess skin after the crushing maneuver (B). The column of excess skin is removed with scissors (C), while the postexcision wound is closed with 6-0 gut suture (D).

A trichloroacetic acid (TCA) 30% peel is another effective means of managing dermatochalasis of the lower eyelid. Patients are informed that the results of a TCA 30% peel are not as dramatic as the results of a laser but their recovery is less complicated. Again, wound care consists of only a petrolatum dressing. The dry wounds from the TCA 30% peel are easier for patients to endure than the raw laser wounds. Patients are informed that the peel can be repeated in 8 to 12 weeks to augment the results if needed.

Skin pinch blepharoplasty is a conservative surgical means of addressing excess lower eyelid skin. With this technique, a band of excess skin (and muscle if desired) can be removed from the lower eyelid to tighten the excess skin. Although this improves the skin wrinkling, it does nothing to improve skin texture or pigmentation like the aforementioned resurfacing procedures. This

approach also has the liability of a surgical scar, but this is usually not an issue as healing progresses well in this area. As the name implies, the skin pinch is performed by crushing or pinching the excess skin between the beaks of a curved hemostat (Figure 5A). The excess skin is estimated and is usually about 3 to 5 mm. The hemostat crushes the skin, which provides hemostasis and a demarcation for the incision line (Figure 5B). After skin has been pinched, the base of the crushed skin column is then excised with Westcott scissors (Figure 5C). At this point the muscle can be addressed if necessary, and the skin incision is closed with interrupted 6-0 gut sutures (Figure 5D). Figure 6 shows a patient before and after skin pinch blepharoplasty and aggressive periorbital CO<sub>2</sub> laser skin resurfacing.

Contemporary treatment of lower eyelid aging involves filling the nasojugal fold or tear trough deformity, as it



**Figure 6.** Patient before (A) and after lower blepharoplasty, with lower lid skin pinch and aggressive periorbital CO<sub>2</sub> laser skin resurfacing (B).

is commonly called. Of interest is the fact that although injectable fillers have been available for 30 years, this particular application has become popular during the last several years. This is in part to the progressive nature of those surgeons who promote minimally invasive treatments. This is also a testament to the influence that pop culture and the media have because a decade ago, patients did not request to have their tear trough sulcus filled.

The author performs tear trough filling as a solitary procedure or in conjunction with the procedures mentioned in this article. Although it sounds counterintuitive to take fat out of the eyelid and then put it back, this technique can improve the hollowed orbit syndrome frequently

seen with blepharoplasty. On occasion, the author will reduce and recontour periorbital fat and concomitantly transfer autologous fat to the nasojugal region. The combination of removing fat in one region and replacing it in another can be powerful in creating natural appearing results. The same can be said for injectable fillers, and by augmenting the nasojugal region in conjunction with cosmetic blepharoplasty a synergistic result may be obtained.

## CONCLUSION

The aging lower eyelid presents a unique challenge to the cosmetic surgeon and results from changes to numerous soft tissues. Fat removal, recontouring, or repositioning combined with procedures that address the lower eyelid skin can provide a more youthful, awake, and alert appearance in patients with senescent periorbital.

## REFERENCES

1. Niamtu J III. Cosmetic blepharoplasty. *Atlas Oral Maxillofac Surg Clin North Am.* 2004;12:91-130.
2. Obagi S, Chaudhary-Patel M. Overview of skin resurfacing modalities. In: Guthoff R, Katowitz JA, eds. *Oculoplastics and Orbit (Essentials in Ophthalmology)*. New York, NY: Springer Berlin Heidelberg; 2007:259-275.
3. Carruthers J, Carruthers A. Shrinking upper and lower eyelid skin with a novel radiofrequency tip. *Dermatol Surg.* 2007;33:802-809.
4. Biesman BS, Pope K. Monopolar radiofrequency treatment of the eyelids: a safety evaluation. *Dermatol Surg.* 2007;33:794-801.
5. Biesman BS, Baker SS, Carruthers J, et al. Monopolar radiofrequency treatment of human eyelids: a prospective, multicenter, efficacy trial. *Lasers Surg Med.* 2006;38:890-898.
6. Niamtu J III. The treatment of vascular and pigmented lesions in oral and maxillofacial surgery. *Oral Maxillofac Surg Clin North Am.* 2004;16:239-254.
7. Lambros VS. Hyaluronic acid injections for correction of the tear trough deformity. *Plast Reconstr Surg.* 2007;120(suppl 6):74S-80S.
8. Nassif PS. Lower blepharoplasty: transconjunctival fat repositioning. *Otolaryngol Clin North Am.* 2007;40:381-390.
9. Niamtu J III. To debride or not to debride? That is the question: rethinking char removal in ablative CO<sub>2</sub> laser skin resurfacing. *Dermatol Surg.* 2008;34:1200-1211.
10. Sukal SA, Chapas AM, Bernstein LJ, et al. Eyelid tightening and improved eyelid aperture through nonablative fractional resurfacing. *Dermatol Surg.* In press. ■